

14th

AICT

ASIAN INTERVENTIONAL CARDIOVASCULAR THERAPEUTICS
THE OFFICIAL CONGRESS OF APSIC

SVG bifurcation and LMCA stenting in cardiogenic shock

Dr Deepak Ameta

Dr Ashok Seth

Fortis Escorts Heart Institute

New Delhi, India



Speaker's name : Deepak, AMETA, Udaipur

I do not have any potential conflict of interest

2018 © AICT Congress 2018. All rights reserved - Any reproduction even in part is prohibited.

2018 © AICT Congress 2018. All rights reserved - Any reproduction even in part is prohibited.

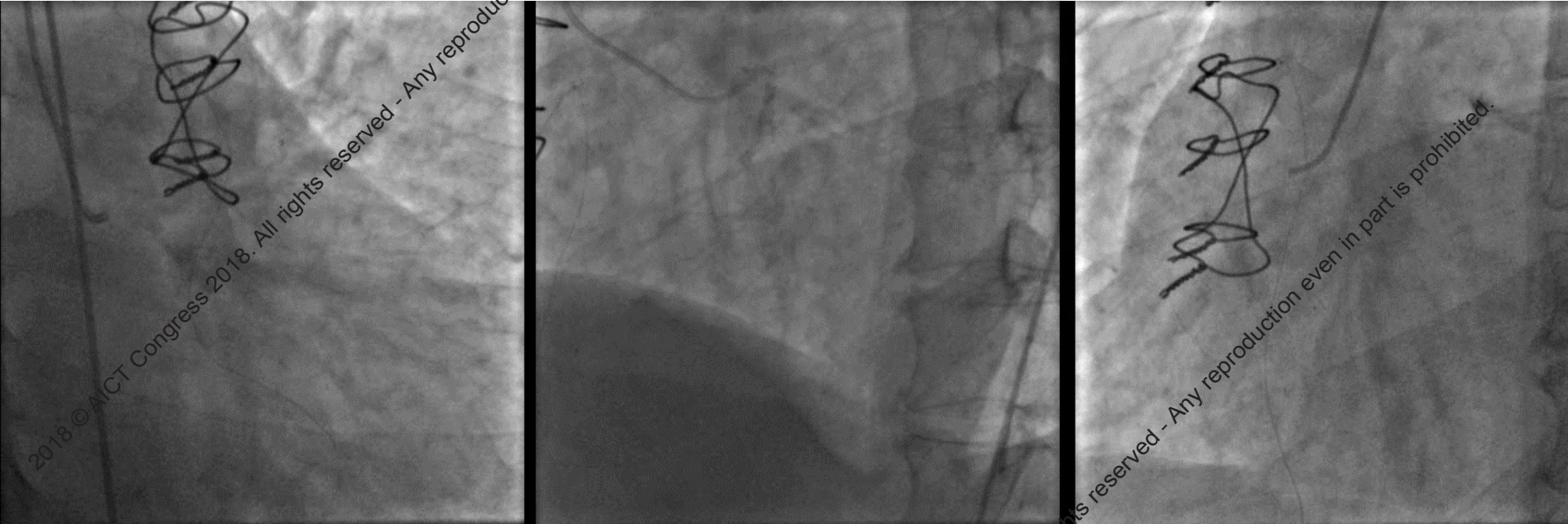
- 70-year old male
- Post CABG status 10 years back (3 SVG grafts with a single origin – 2 more SVG grafts were anastomosed end to side to main graft and was supplying to LAD, OM and PDA)
- Normal LVEF
- Currently, admitted with ACS, LVF and cardiogenic shock
- Stabilised initially and then taken up for CAG

2018 © AICT Congress 2018. All rights reserved. Any reproduction even in part is prohibited.

2018 © AICT Congress 2018. All rights reserved. Any reproduction even in part is prohibited.



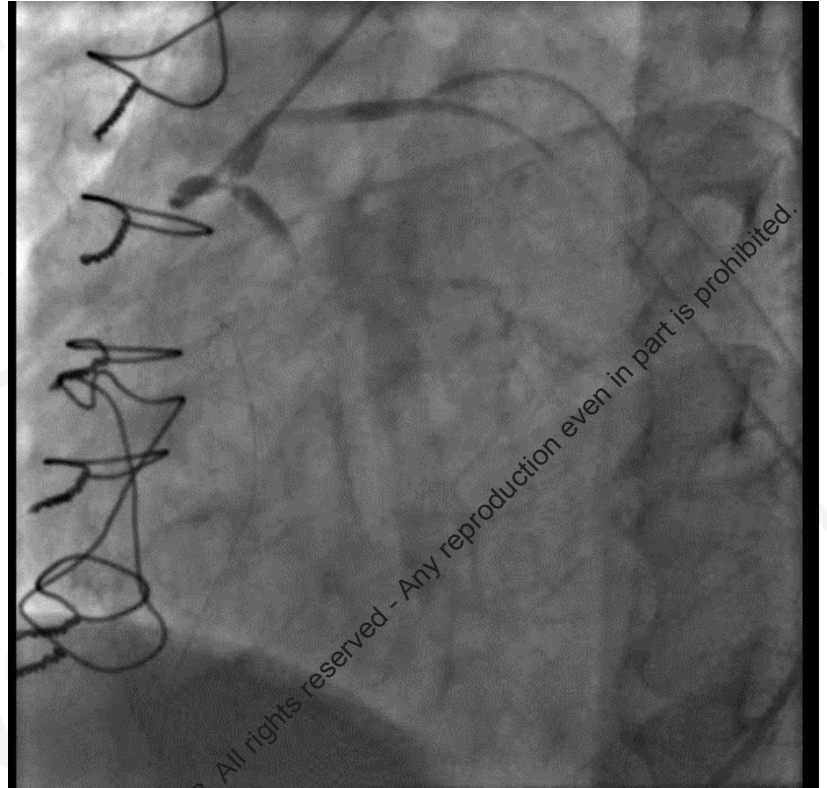
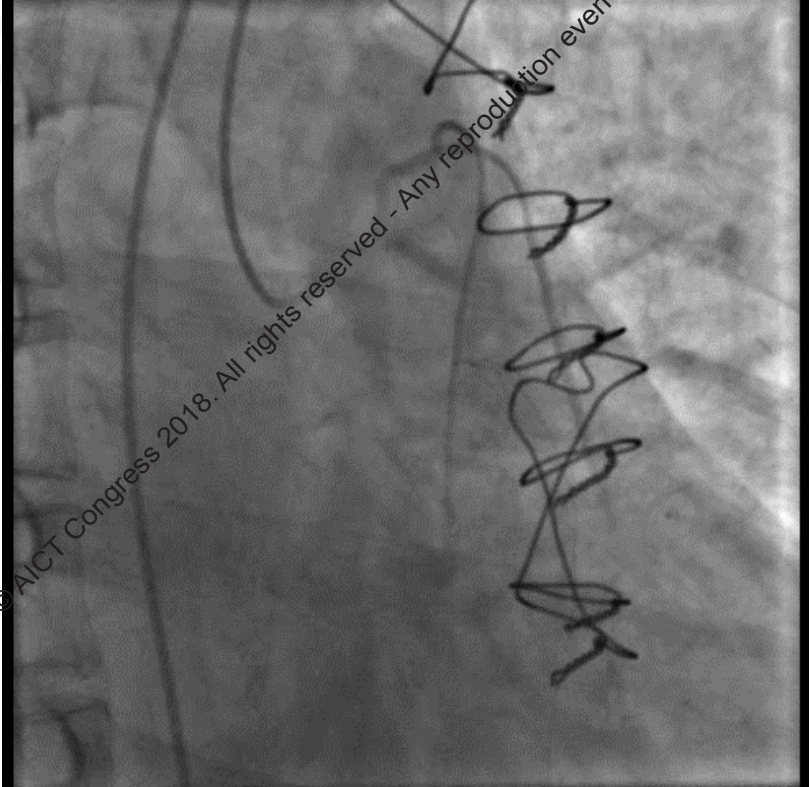
CAG showed severe native TVD with one unsupported LPLV



2018 © AICT Congress 2018. All rights reserved - Any reproduction even in part is prohibited.

2018 © AICT Congress 2018. All rights reserved - Any reproduction even in part is prohibited.

2018 © AICT Congress 2018. All rights reserved - Any reproduction even in part is prohibited.

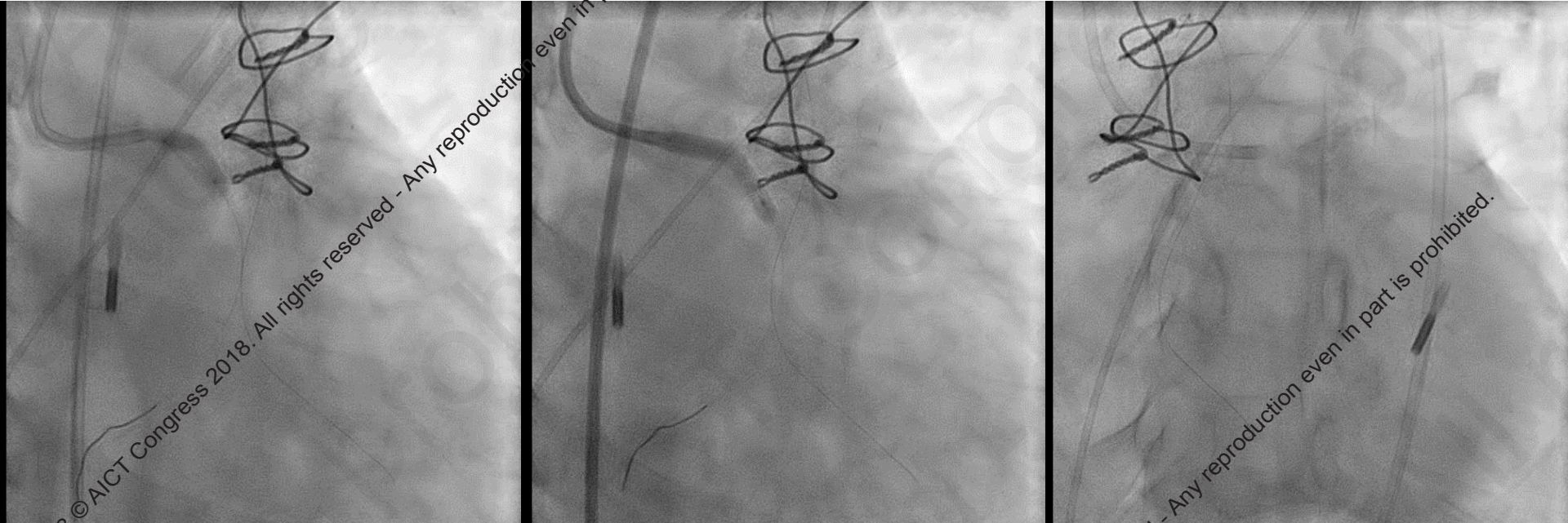


The SVG grafts were critically occluded at the bifurcation and the common ostium

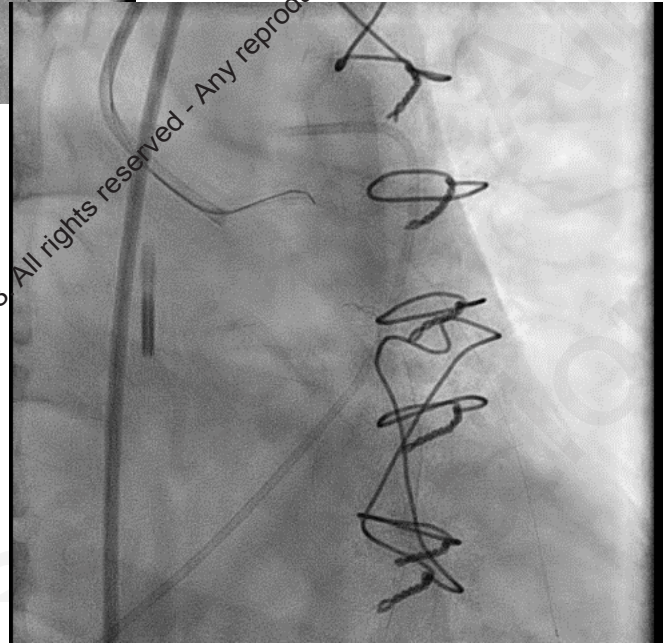
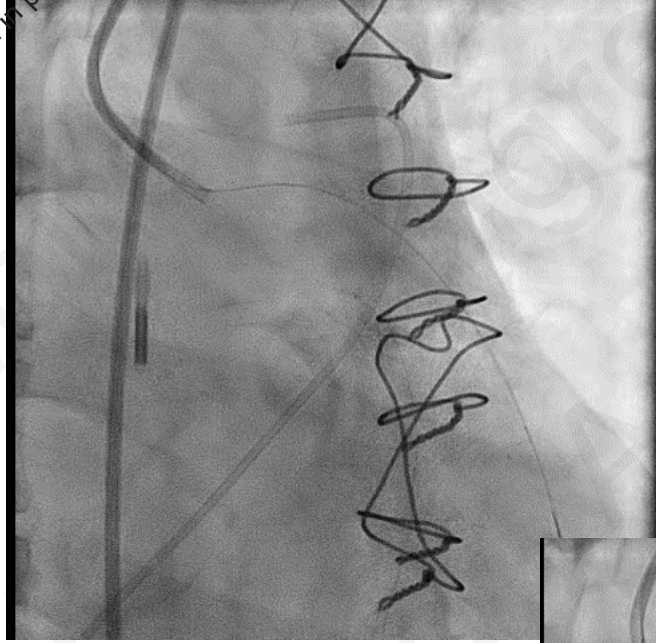
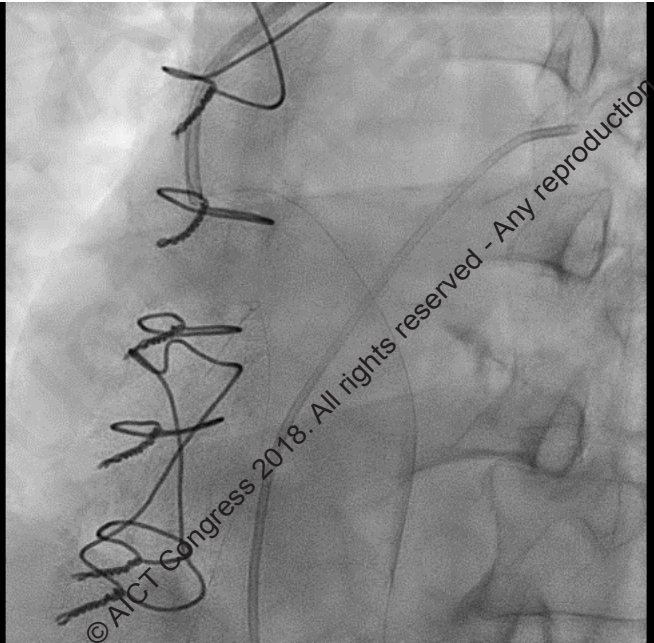
- A strategy of complete revascularisation was chosen
- IABP was placed
- A PA catheter was also in place
- Plan of LM to LCX and SVG graft bifurcation stenting was planned

2018 © AICT Congress 2018. All rights reserved - Any reproduction even in part is prohibited.

2018 © AICT Congress 2018. All rights reserved - Any reproduction even in part is prohibited.



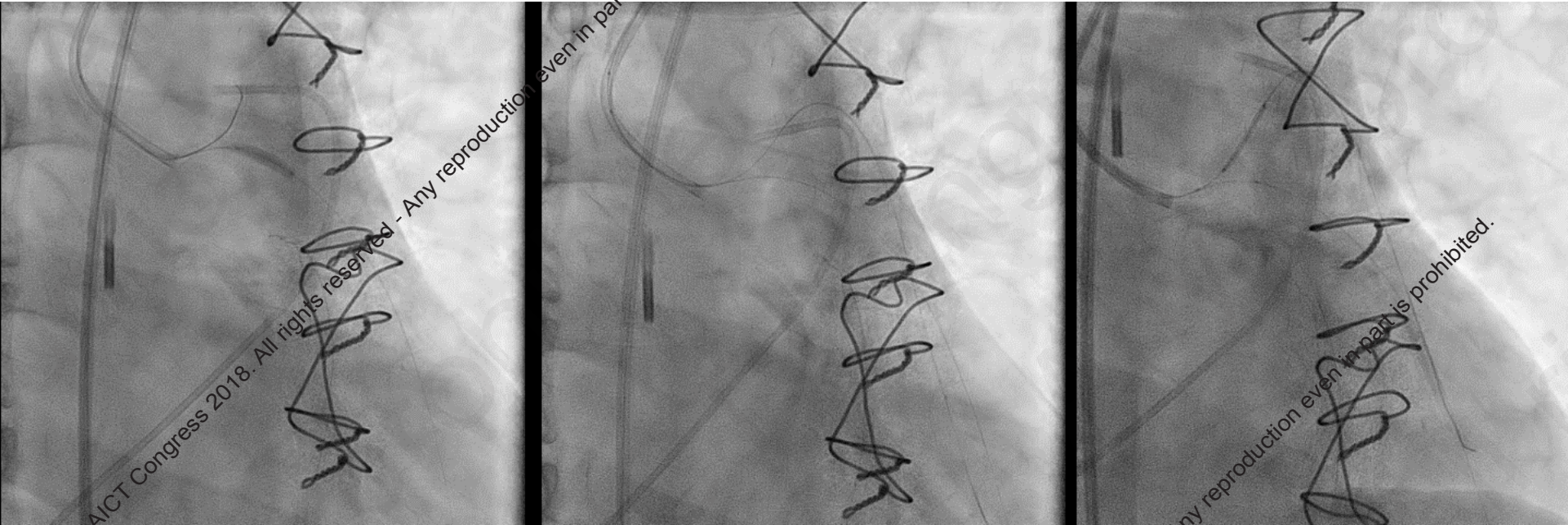
- DES 3.5 x 28 mm implanted from LM to LCx;
- Post dilated from 4.0 mm balloon at high pressure



- Guide: Multipurpose
- Wire BMW

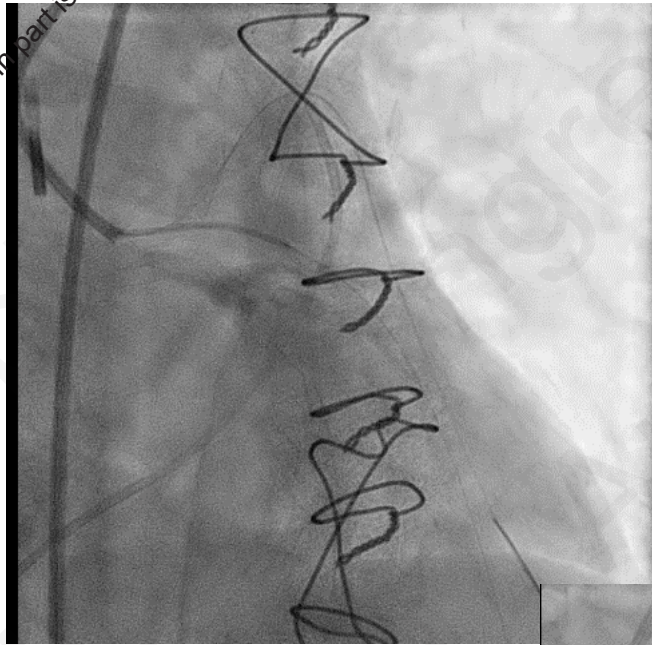
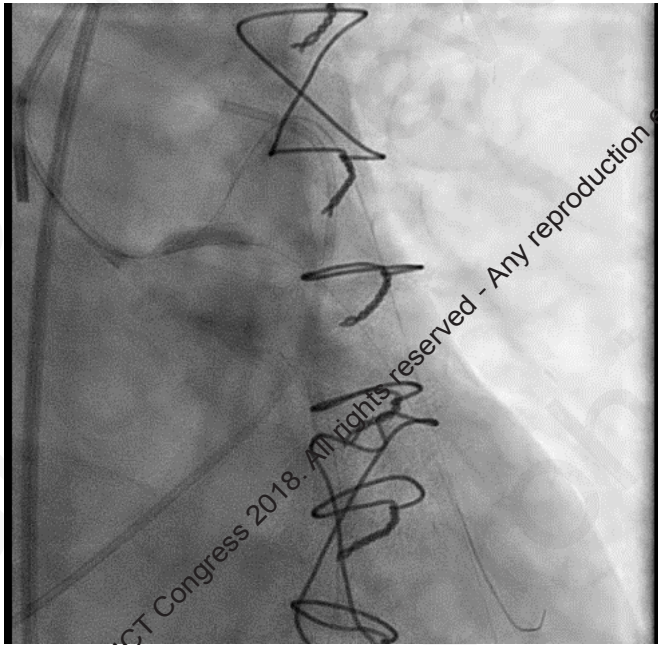
2018 © AICT Congress 2018. All rights reserved - Any reproduction even in part is prohibited.

2018 © AICT Congress 2018. All rights reserved - Any reproduction even in part is prohibited.

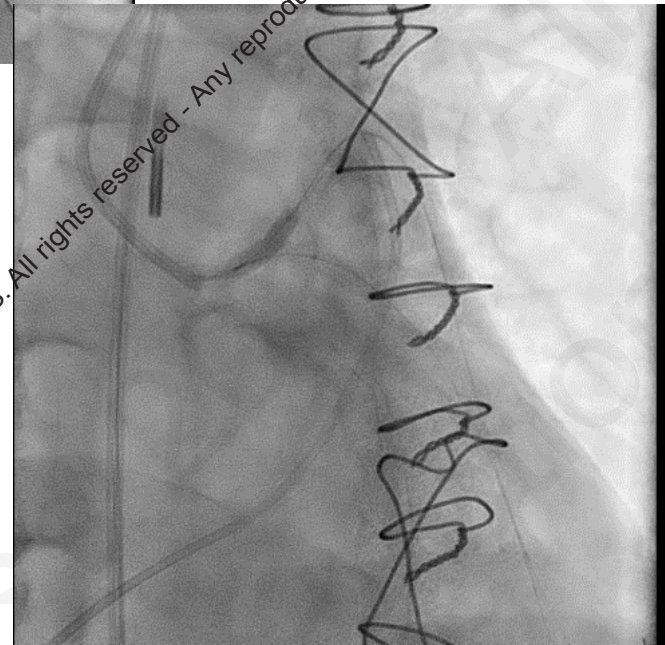


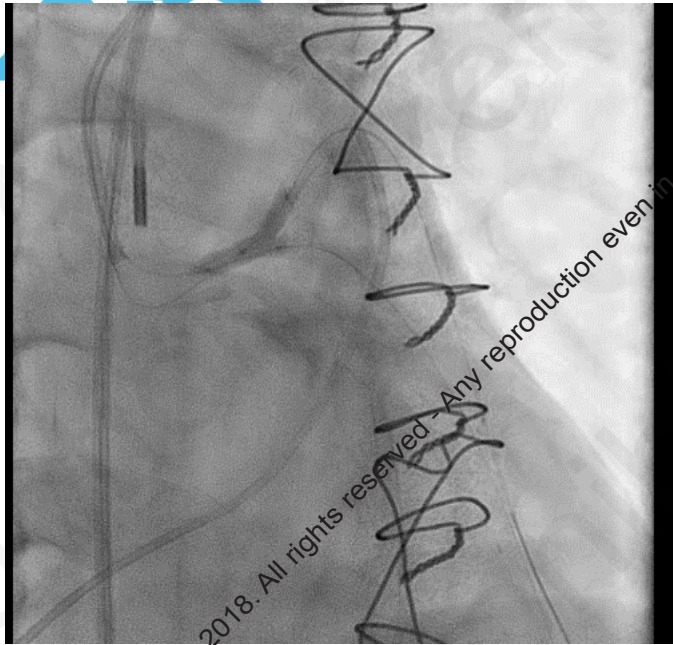
- Entry of wire in branch via deflection from balloon in main branch
- Pre-dilated both branches

DES 3.0 x 18 in branch

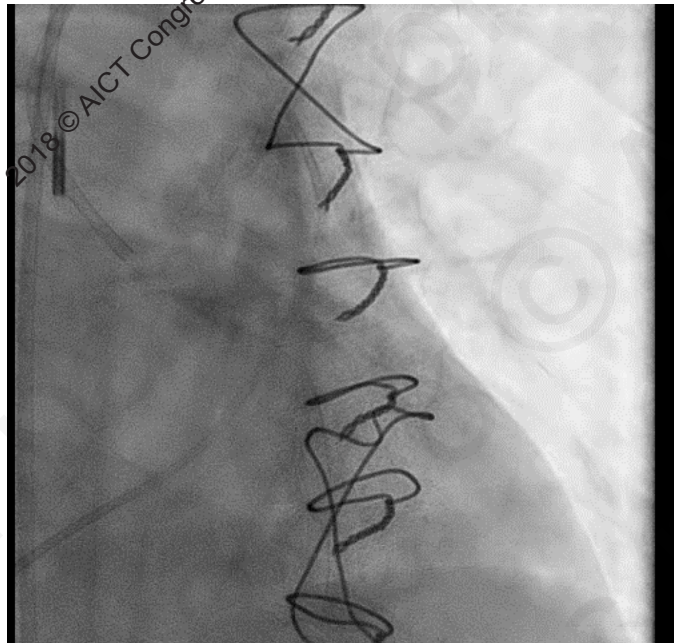
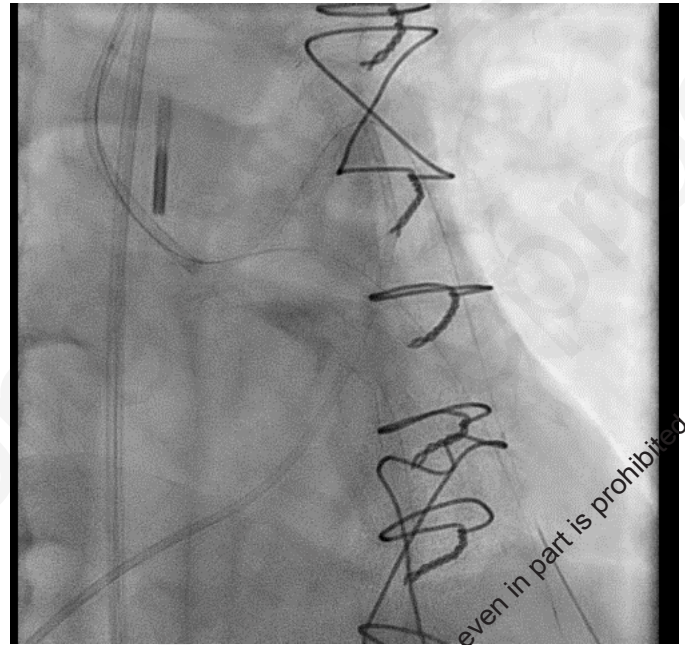


- Mini Crush with 2.5 mm balloon
- Another DES 3.0 x 23 from ostium to main branch

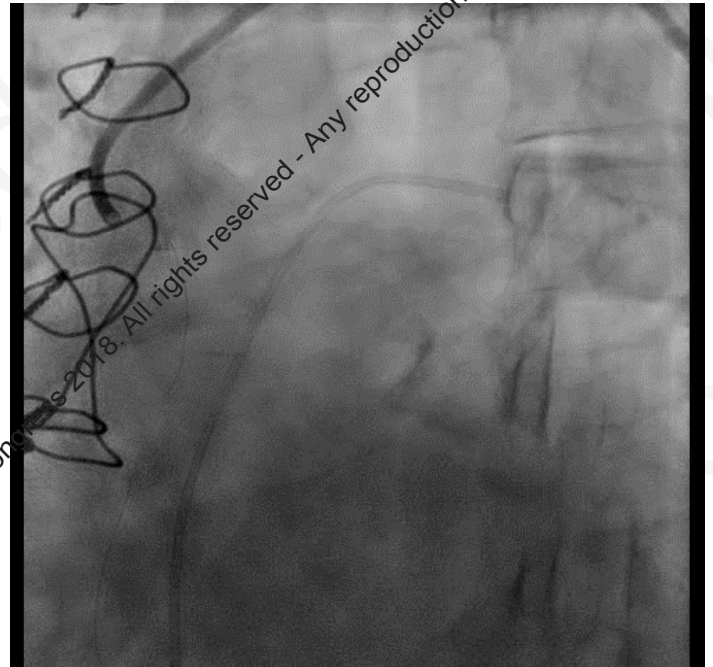




Simultaneous kissing balloon inflation



Final result



Learning points

- Bifurcation strategies are used in the same way as they are used in native vessels
- Complete revascularisation is the key to improve the prognosis
- Prior treating such grafts through which large myocardium is at jeopardy, we should try to fix any one native vessel as fast as possible
- IABP is must during such procedures

2018 © AICT Congress 2018. All rights reserved - Any reproduction even in part is prohibited.

2018 © AICT Congress 2018. All rights reserved - Any reproduction even in part is prohibited.



2018 © AICT Congress 2018. All rights reserved - Any reproduction even in part is prohibited.

Thank You

2018 © AICT Congress 2018. All rights reserved - Any reproduction even in part is prohibited.

14th

AICT

ASIAN INTERVENTIONAL CARDIOVASCULAR THERAPEUTICS
THE OFFICIAL CONGRESS OF APSIC

7 - 9th September 2018

Hong Kong

Convention and Exhibition Centre (HKCEC)

2018 © AICT Congress 2018. All rights reserved - Any reproduction even in part is prohibited.

2018 © AICT Congress 2018. All rights reserved - Any reproduction even in part is prohibited.